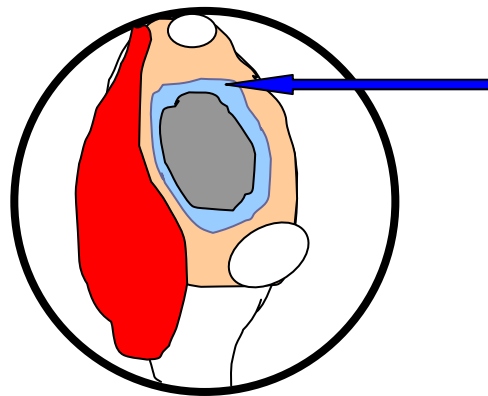


Transnasal Endoscopic Sinonasal **Surgery**



27 Illustrations

Cadaveric Dissection Guide

Reda Kamel
Professor of Rhinology
Cairo University – Egypt

Acknowledgement

I would like to thank Dr. Tarek Kandiel, Dr. Ashraf Khaled and Dr. Hany El-Gamal for their great advise, help and support in revising and editing this cadaveric guide.

Special appreciation to my wife and three daughters who missed a lot of time and care because of this work.

**Reda Kamel
Professor of Rhinology
Cairo University
Egypt**

Cadaveric dissection under supervision is the best way of training in endoscopic sinus surgery.

*** Be ready:**

Before you go to the cadaveric dissection room be ready:

A- *Anatomical Basics:*

You have to have good anatomical basis concerning:

1. Lateral nasal wall
2. Skull base
3. Nasopharynx

B- *Instruments:*

You have to make sure that you have the essential instruments:

- 0° and 30° telescopes
- Light source and cable
- Sickle knife
- Forward cutting forceps
- Upward cutting forceps
- Backward cutting forceps
- Suction tips, straight and curved

*** Help your fellow:**

It is very wise to act as an assistant to your fellow during his turn and follow him in the monitor. This gives you more orientation and better chance during your turn.

*** Go:**

You have to plan how to make full use of the dissection session. You have to proceed into the following:

- I- Diagnostic endoscopy
- II- Maxillary sinuscopy
- III- Functional endoscopic sinus surgery and pansinus surgery
- IV- Identifications of the sinonasal limits which should be respected to avoid complications
- V- Advanced endoscopic techniques [in the advanced course]

I - Do Diagnostic Endoscopy:

(1) Use the 0° lens to get an overall view of the nasal cavity and define the following:

1. Nasal septum
2. Nasal floor
3. Inferior turbinate (IT)
4. Middle turbinate (MT) [Fig. 1]

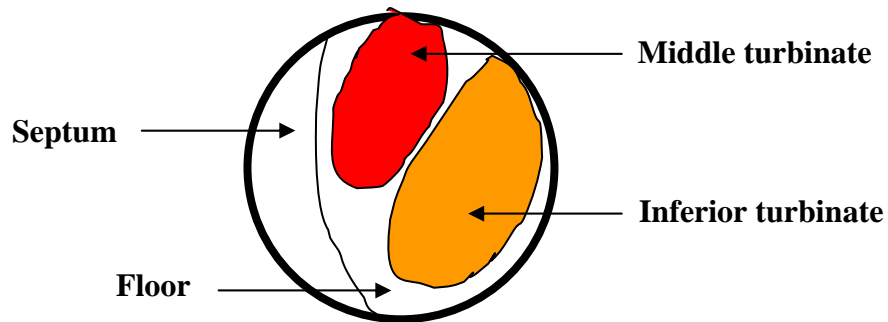


Fig. 1- Overall view of left nasal cavity [endoscopic]

(2) Then use the straight suction tip to clear the nose and nasopharynx (NP) off the blood and secretions. You may need saline irrigation to help liquefy matters.

(3) Introduce the O⁰ lens below the inferior turbinate into the inferior meatus towards the nasopharynx. Examine the nasopharynx meticulously and visualize:

1. Ipsilateral Eustachian tube (ET)
2. Ipsilateral fossa of Rosenmuller
3. Roof of nasopharynx
4. Posterior wall of nasopharynx
5. Contralateral fossa of Rosenmuller
6. Contralateral Eustachian tube [Fig.3]

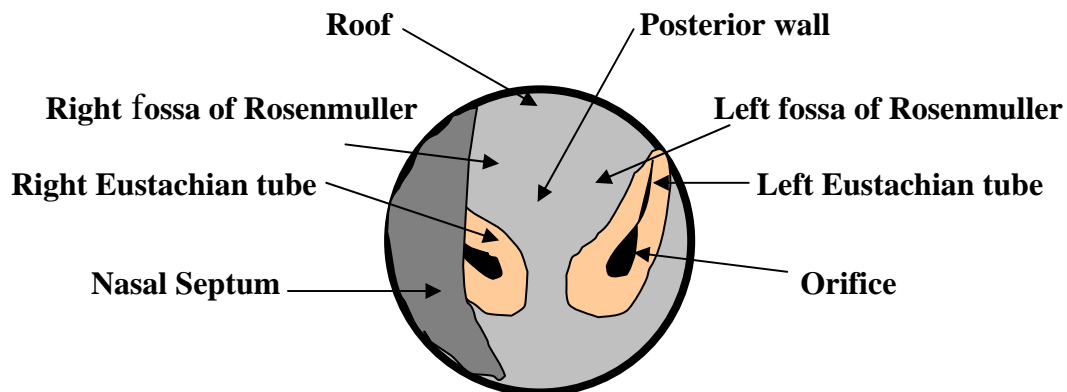


Fig. 3- The nasopharynx as seen through the left nasal cavity [endoscopic]

(4) Identify the boundaries of the choana:

1. Inferior: nasal floor
2. Medial: nasal septum
3. Superior: sphenoid sinus
4. Laterally: medial pterygoid plate [Fig. 4]

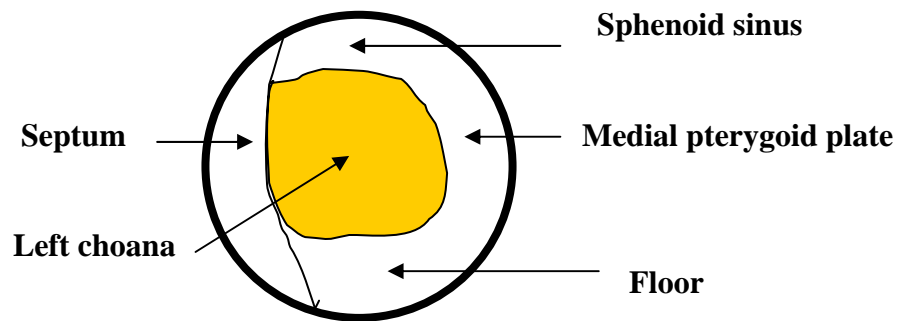


Fig. 4- Boundaries of left choana [endoscopic]

(5) Get out slowly and follow the inferior meatus. Look for the nasolacrimal duct (NLD) orifice. Press on the lacrimal sac from outside and notice air bubbles and/or tears from the NLD orifice.

(6) Then introduce the endoscope towards the middle turbinate and identify:

1. Agger nasi bulge (AN)
2. Neck of middle turbinate
3. Uncinate process (UP)
4. Bulla ethmoidalis (BE) [Fig. 6]

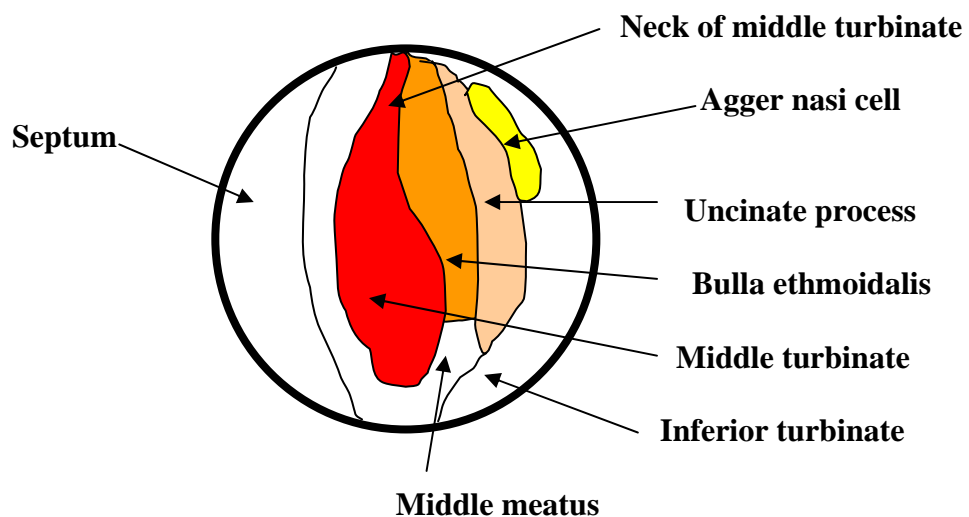


Fig. 6- Left ostiomeatal complex [endoscopic]

(7) Introduce your endoscope transnasally and localize the agger nasi cells. Then detach the light cable from the endoscope and keep the endoscope in place. Then apply the tip of the light cable on the lacrimal fossa from outside, just posterior to the anterior lacrimal crest. Notice the light transmission (transillumination) into the nasal cavity. This is a guide to the site of the lacrimal sac.

(8) Introduce the 0° lens into the middle meatus (MM) between the inferior turbinate and the middle turbinate. Then identify:

- Hiatus semilunaris inferior (HSI), two dimensional [the door]
- Ethmoid infundibulum, three dimensional [the room] [Fig. 8]

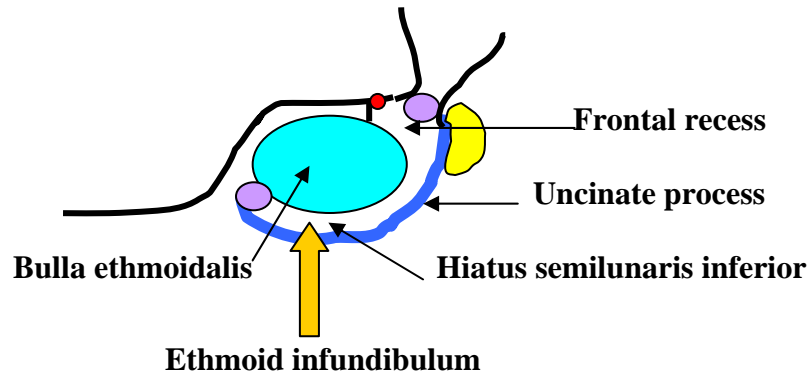


Fig. 8- Left hiatus semilunaris inferior and ethmoid infundibulum [diagram-sagittal]

(9) Then define the hiatus semilunaris inferior between the bulla ethmoidalis posteriorly and the uncinete process anteriorly. Proceed far anterior and superior to the expected site of frontal recess and far posterior and inferior to the expected site of maxillary sinus ostium.

(10) Introduce the 30° lens into the middle meatus below bulla ethmoidalis to bulla–uncinate angle posteriorly. Now try to localize the maxillary ostium (MO). Use the curved suction tip as a guide to the maxillary ostium and introduce it inferiorly and laterally into the maxillary sinus (MS). Move the suction tip up and down and notice the eye from outside.

- If you felt bone upward and space downward, you are in the wright way, you are inside the maxillary sinus
- But if you noticed eye movement upward and bone downward, you are in the wrong way. You are inside the orbit, remove suction tip, take care and try again few mm down. This is mentioned to be condemned [Fig. 10]. **TAKE CARE**

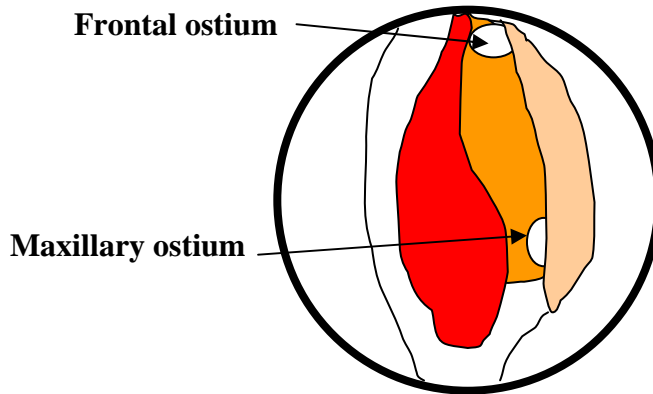


Fig. 10- Left maxillary and frontal ostia [endoscopic]

(11) Introduce the 30° lens into the middle meatus anterior to the bulla ethmoidalis to the bulla–uncinate angle anteriorly. Then localize the frontal recess (FR) and frontal sinus ostium (FO). Use the curved suction tip as a guide to frontal ostium and try to introduce it superiorly and laterally into the frontal sinus (FS) [Fig. 10].

(12) Look for the anterior ethmoid artery (AEA) and the supra orbital air cell just behind the frontal ostium and anterior to bulla ethmoidalis.

- (13) Proceed medial to bulla ethmoidalis towards the basal lamella (ground lamella). Try to identify:
- Hiatus semilunaris superior (HSS), two dimensional [the door]
- Lateral sinus (LS), three dimensional [the room] [Fig. 13]

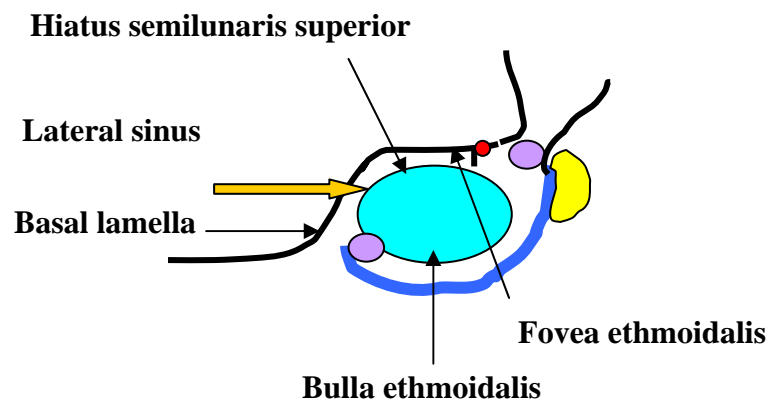


Fig. 13- Left lateral sinus and hiatus semilunaris superior

(14) Then trace lateral sinus behind bulla ethmoidalis [retrobullar recess] and above bulla ethmoidalis [suprabullar recess] anteriorly towards frontal recess.

(15) Introduce the O⁰ lens medial to the middle turbinate and lateral to the nasal septum into superior meatus and sphenoidal recess. Try to identify:

1. Posterior ethmoids (PE)
2. Sphenopalatine foramen (posterior to the posterior end of the middle turbinate).
3. Superior turbinate
4. Sphenoid sinus ostium (SO).

(16) Get out and trace the cribriform plate between the middle turbinate and the nasal septum.

II- Do Maxillary Sinuscopy:

(17) Use the trocar and canula to penetrate the sublabial mucosa and place your trocar tip on the upper lateral angle of the canine fossa, which is the thinnest part of bone. Apply rotatory movement perpendicular to the anterior wall of the maxillary sinus, parallel to the nasal septum and orbital floor. Do it slowly and gently and avoid any sudden penetration. Remove the trocar and leave the canula.

(18) Introduce the 30⁰ lens through the canula and identify:

1. Medial wall: maxillary ostium and accessory ostium/ostia, if any
2. Superior wall - Inferior orbital nerve
3. Lateral wall
4. Floor
5. Posterior wall

(19) Introduce the curved suction tip through the maxillary ostium transnasally at bulla uncinata angle posteriorly. Visualize it through the maxillary sinuscopy. Move the suction tip superiorly to feel the orbital bony floor and notice how close it is [site of the middle meatal antrostomy (MMA)]. If suction tip is introduced inadvertently into the orbit, upward movement will give rise to eye movement [uncovered patient's eye & alertness of nurse] and downward movement leads to feeling of a hinder of orbital floor [no cavity].

STOP, REVISE, REMOVE TIP IMMEDIATELY

III- Do Functional Endoscopic Sinus Surgery (FESS) and Pansinus Surgery

(20) Use the O⁰ lens to identify:

1. Agger nasi cell
2. Uncinate process
3. Neck of middle turbinate

Determine the site of injection anterior and superior to the neck of middle turbinate and uncinata process [Fig. 20].

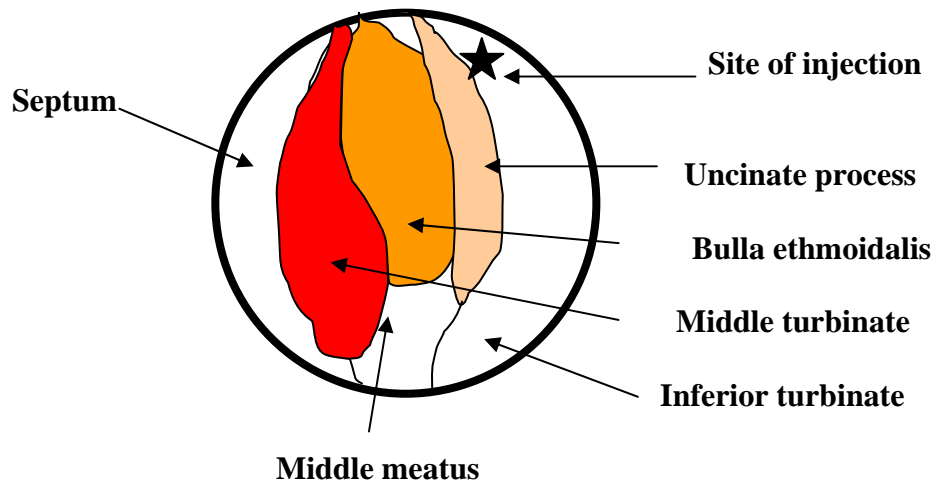


Fig. 20- Ostiomeatal complex

(21) Palpate the uncinete process to determine the site of incision using the Freer dissector. Incise the uncinete process at its middle and proceed posteriorly and inferiorly then anteriorly and superiorly using the sickle knife. Then remove the uncinete process using the thru cutting forceps superiorly and anteriorly at the frontal recess and posteriorly and inferiorly at maxillary ostium. Notice that mild dislocation of the middle turbinate may be needed [Fig. 21].

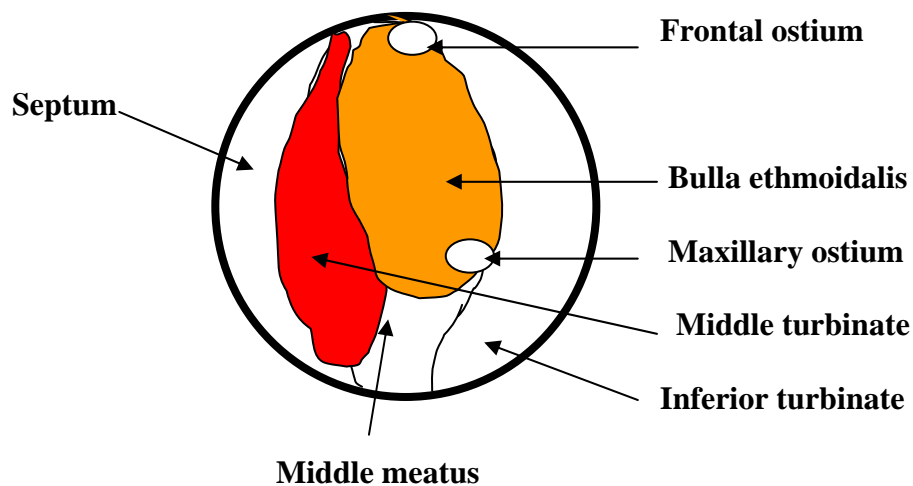


Fig. 21- Left uncinete process excised

(22) Use the 30° endoscope to identify the maxillary ostium between the remnant of the uncinete process posteroinferiorly and the bulla ethmoidalis and try to cannulate it [Fig. 22]. **[Take care of the orbit]**

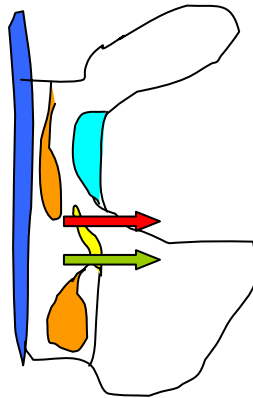


Fig. 22 – Middle meatal anastomy: safe entry green arrow, orbital insult red arrow [diagram - coronal]

(23) Use the 30° endoscope to identify the frontal ostium between remnant of the uncinate process anterosuperiorly and the middle turbinate and try to cannulate it [Fig. 23]. [**Take care of the skull base**]

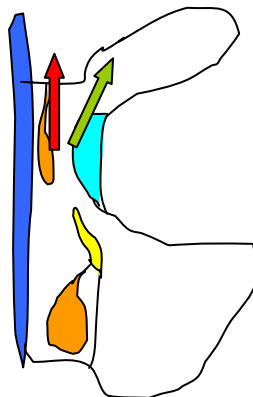


Fig. 23 – Cannulation of the frontal ostium: safe entry green arrow, cranial insult red arrow [diagram - coronal]

(24) Try to identify the following structures posterior to the frontal ostium:

1. Supraorbital air cell
2. Anterior ethmoid artery
3. Fovea ethmoidalis (FE)
4. Lateral lamella (LL)
5. Suprabullar lamella
6. Bulla ethmoidalis [Fig. 24]

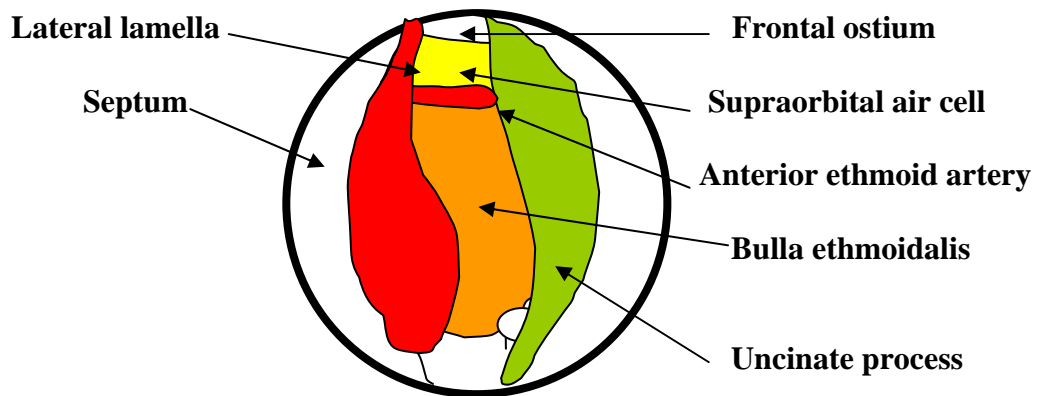


Fig. 24- Left middle meatal antrostomy MMA

(25) Widen the maxillary ostium to perform middle meatal antrostomy [MMA]:

1. Posteriorly to posterior wall of maxillary sinus using the forward forceps
2. Superiorly to orbital floor using the forward forceps
3. Anteriorly to nasolacrimal duct using the backward forceps
4. Inferiorly to the inferior turbinate using the forward forceps [Fig. 25]

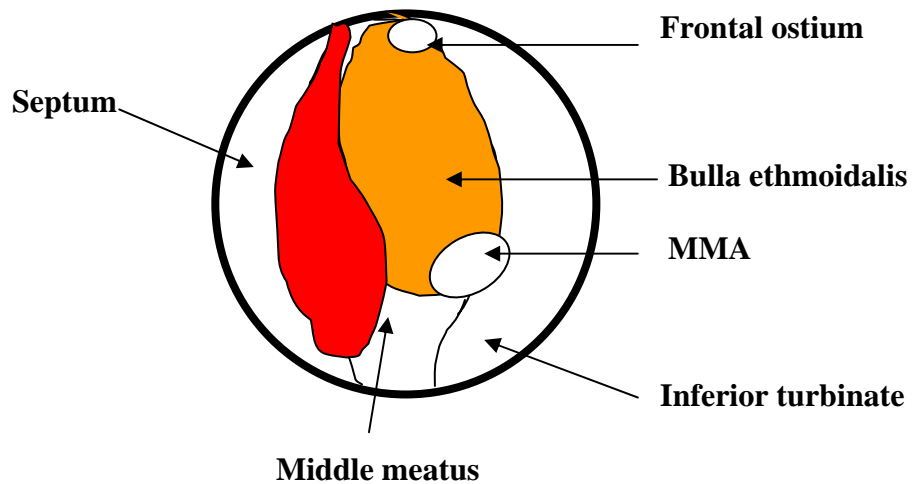


Fig. 25- Left middle meatal antrostomy MMA

(26) Shift to the 30⁰ lens and introduce it through the maxillary ostium into the maxillary sinus. Visualize the canula that was introduced through the canine fossa and examine the maxillary sinus cavity and walls.

(27) Return to the O^0 lens and penetrate the bulla ethmoidalis inferomedially [safest] using the straight suction tip. Uncap the bulla ethmoidalis anterior wall and remove its contents using the forward forceps. Identify the lamina papyracea laterally [yellowish] [Fig.27].

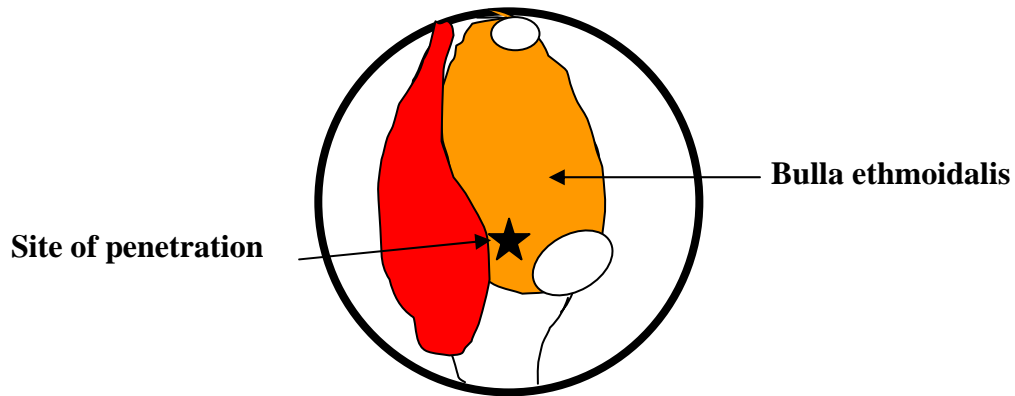


Fig. 27-Left bulla ethmoidalis penetrated

(28) Remove the rest of the bulla ethmoidalis:

1. Medial wall and notice its close relation to the middle turbinate
2. Inferior wall and notice its relation to the middle meatal antrostomy
3. Posterior wall and notice its relation to the lateral sinus [retrobullar recess] and basal lamella
4. Superior wall and notice its relation to the lateral sinus [suprabullar recess] and fovea ethmoidalis [skull base] [Fig. 28]

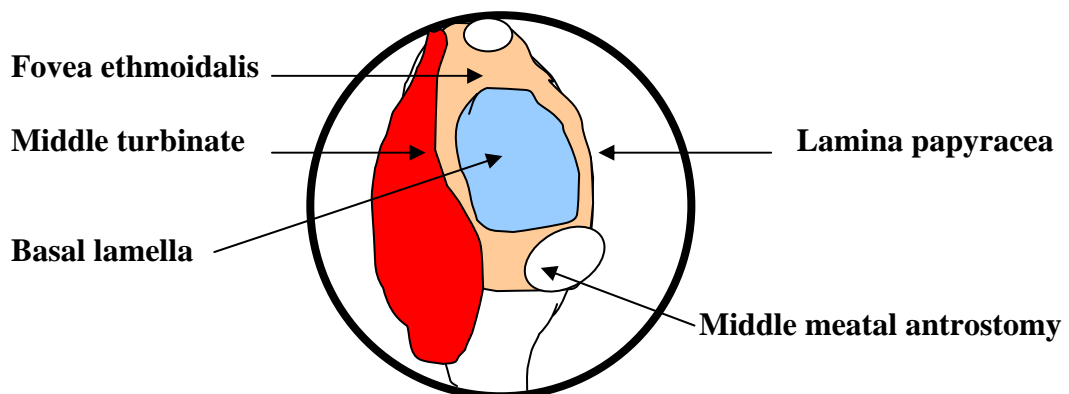


Fig. 28- Left bulla ethmoidalis removed and basal lamella exposed

(29) Now you can notice the difference in **color**:

1. Lateral: lamina papyracea (yellowish)
2. Superior: fovea ethmoidalis (whitish)
3. Posterior: basal lamella (reddish)

(30) Trace Fovea Ethmoidalis:

1. Anteriorly to:
 - anterior ethmoid artery.
 - supraorbital air cell
 - frontal ostium [Fig. 30,a]
2. Medially to: lateral lamella [**carefully**] [Fig. 30,b]

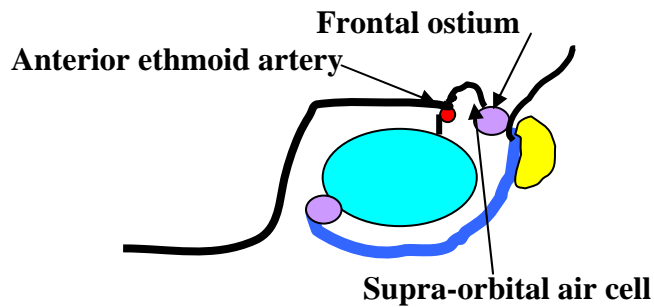


Fig. 30,a- Supraorbital cell and anterior ethmoid artery

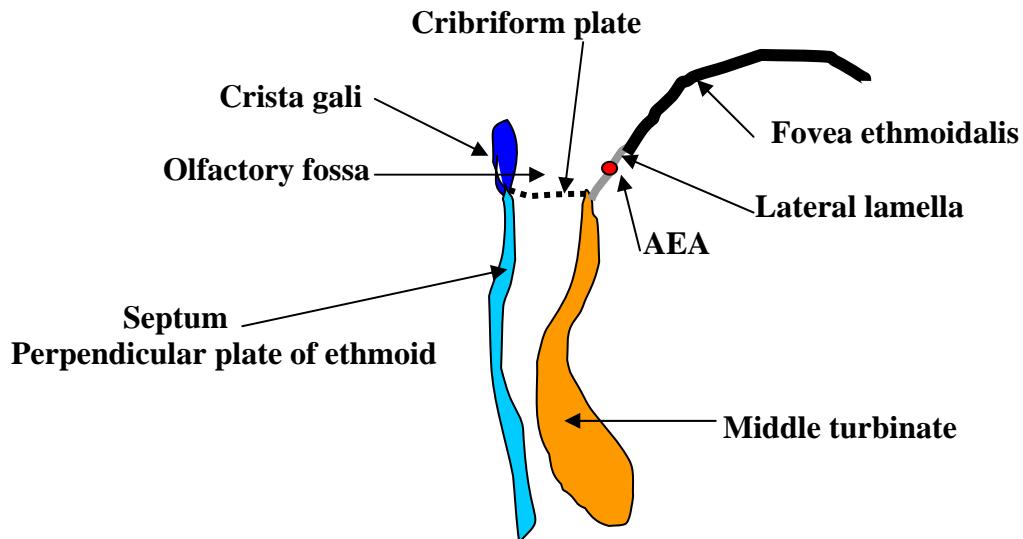


Fig. 30,b- Fovea ethmoidalis and lateral lamella

(31) Now you can notice the difference in **thickness**:

1. Fovea ethmoidalis (hard)

2. Lateral lamella (very thin)
3. Lamina papyracea (thin)

(32) Use the 30⁰ lens to visualize the frontal ostium and frontal sinus.

(33) Return to the O⁰ lens and define the boundaries of the basal lamella:

1. Superiorly: skull base, fovea ethmoidalis
2. Laterally: lamina papyracea
3. Inferiorly: the junction between 3rd and 2nd parts of the middle turbinate
4. Medially: the junction between the 1st and 2nd parts of the middle turbinate

[Fig. 33]

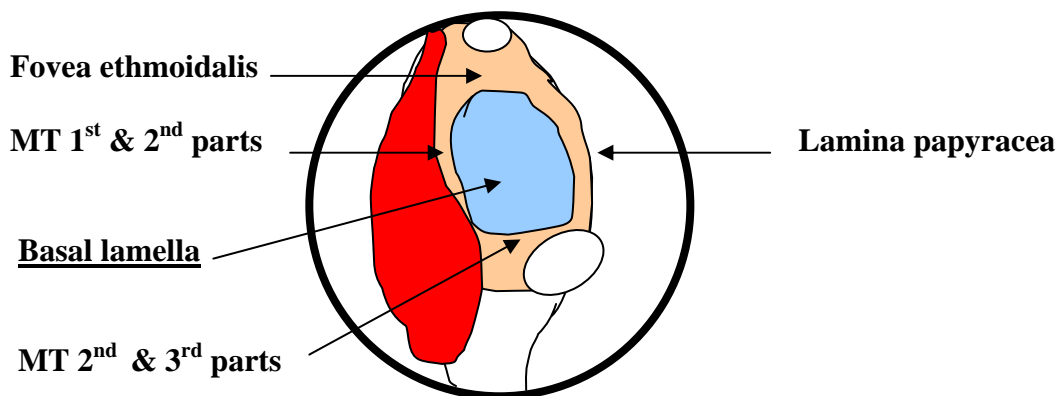
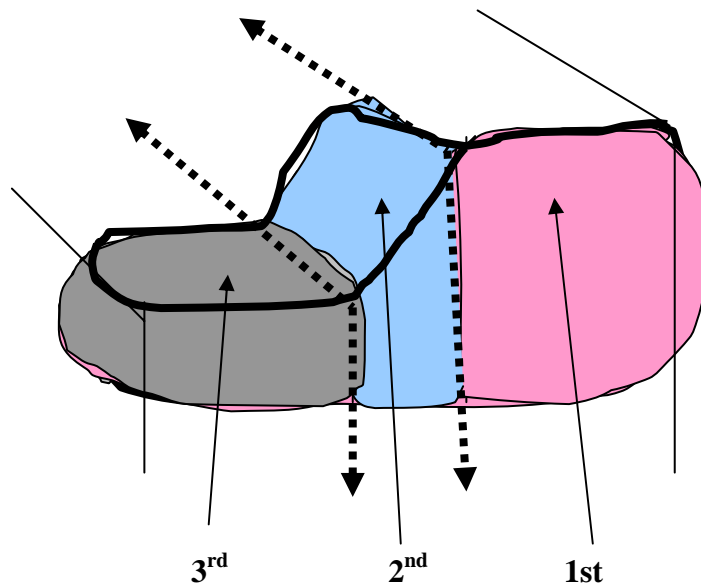


Fig. 33-Left basal lamella boundaries

(34) Notice that the middle turbinate is composed of three parts:

Part	Site	Direction	Attachment
1 st part	(anterior)	Vertical	Skull base
2 nd part	(middle)	Oblique	Lamina papyracea
3 rd part	(posterior)	Transverse	Perpendicular plate of palatine Bone



34- Middle turbinate three parts

(35) Penetrate the basal lamella inferomedial, which is the safest site, from the anterior ethmoids to the posterior ethmoids. Remove the contents of the posterior ethmoids using the straight suction tip and forward cutting forceps [Fig. 35]. Introduce the suction tip into the superior meatus to the posterior ethmoids and visualize it while the endoscope present into the middle meatus. Then do the reverse, introduce the suction tip through the middle meatus into the posterior ethmoids and visualize it while the endoscope into the superior meatus.

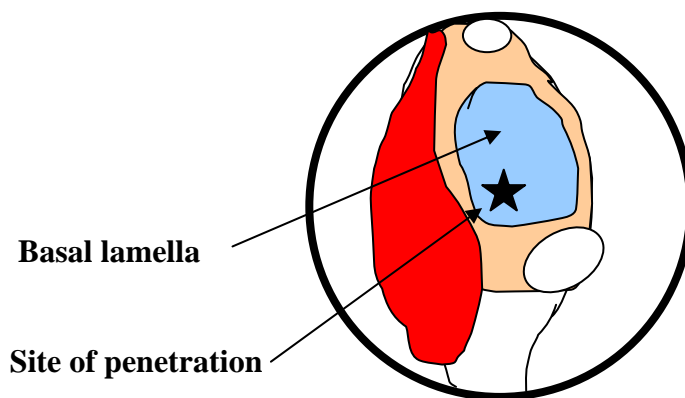


Fig. 35- Site of penetration of left basal lamella

(36) Remove the basal lamella cautiously using the forward cutting forceps. Be aware that:

1. Laterally: lamina papyracea and orbit
2. Superiorly: fovea ethmoidalis and skull base

(37) Remove the posterior ethmoid cells and define their boundaries and notice the differences in color:

1. Superiorly: skull base (whitish)
2. Laterally: lamina papyracea (yellowish)
3. Posteriorly: face of sphenoid sinus anterior wall (bluish) [Fig. 37]

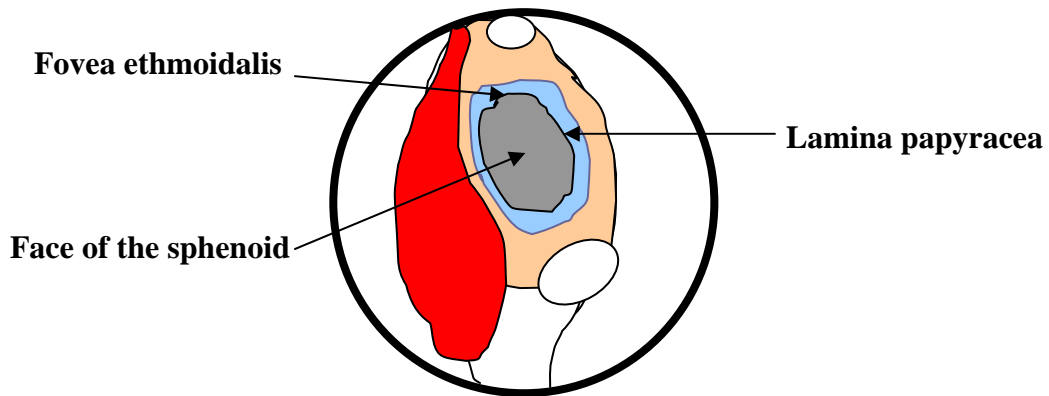


Fig. 37-Left posterior ethmoids boundaries after removal of the basal lamella

(38) Look for the posterior ethmoid artery (PEA) anterior to the junction of the roof of the posterior ethmoids and the anterior wall of sphenoid sinus.

(39) Identify the critical angle laterally between roof, post wall, and lateral wall of posterior ethmoids [Fig. 39]. ()

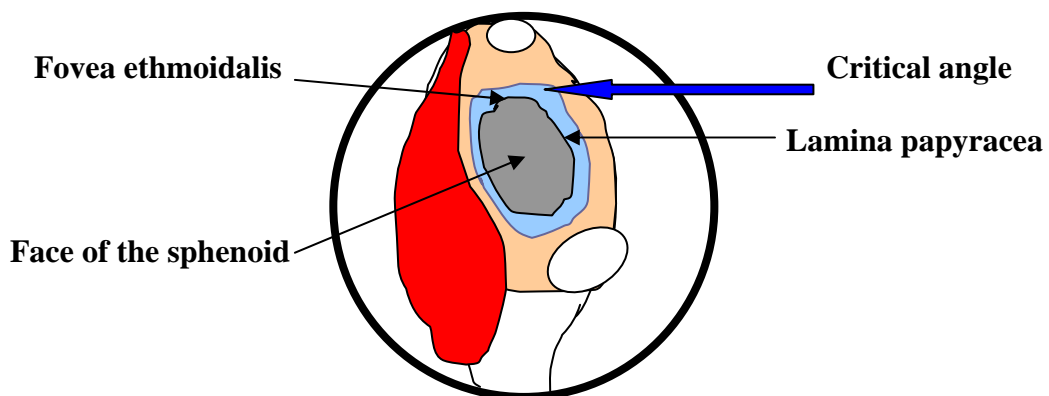


Fig. 39-Left critical angle

(40) Then identify:

1. Anterior wall of the sphenoid sinus through the posterior ethmoids.
2. Sphenoid sinus ostium through the sphenoethmoidal recess.

A- Introduce your suction tip just medial to the posterior end of the superior turbinate, OR

B- Follow the floor of the sphenoid sinus which is the roof of the nasopharynx and proceed to the anterior wall of the sphenoid sinus up for few mm [Fig. 40].

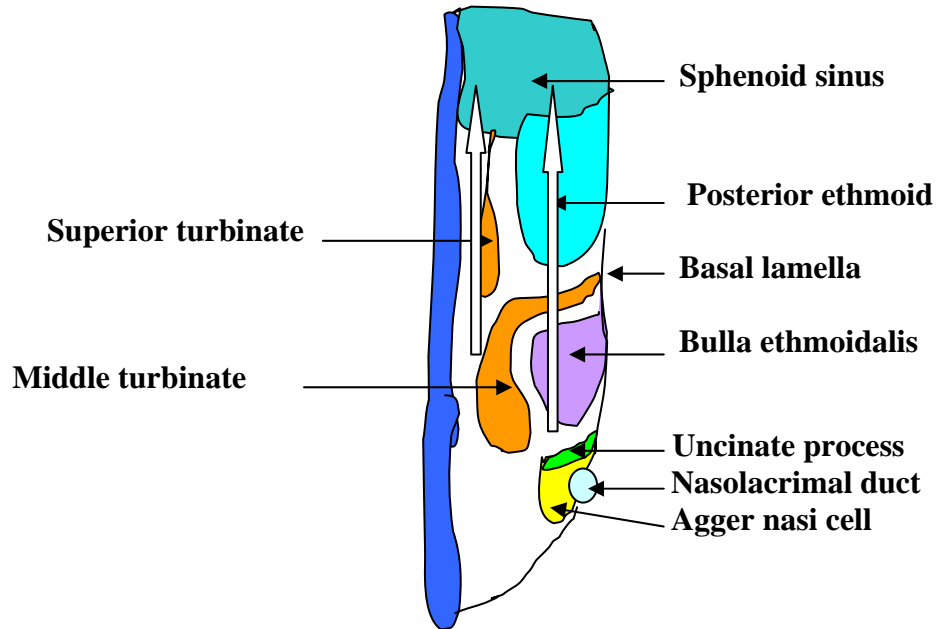


Fig. 40- Sphenoidotomy through the posterior ethmoids or the sphenoethmoidal recess

(41) Penetrate the anterior wall of the sphenoid sinus through the posterior ethmoids inferomedially using the suction tip. This is the safest area. Then widen this opening superiorly and laterally using the sphenoid forceps or mushroom forceps. Then communicate the sphenoidotomy to the sphenoid sinus ostium medially. This usually entails resection of the inferior part of the superior turbinate. Avoid sudden penetration of the anterior wall of the sphenoid sinus to avoid any insult to the optic nerve (ON) and/or internal carotid artery (ICA) [Fig. 41].

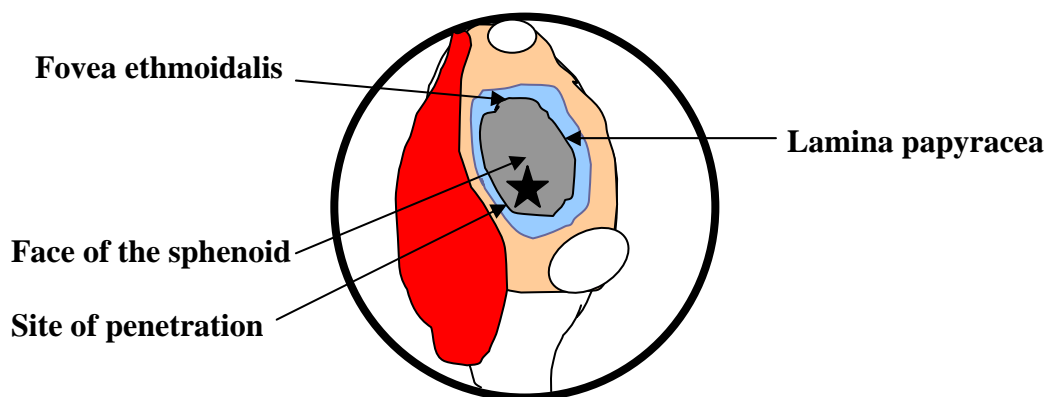


Fig. 41- Site of penetration of the anterior wall of the sphenoid sinus

(42) Introduce the endoscope inside the sphenoid sinus and define:

1. Optic Nerve (ON): laterally and superiorly and trace it medially to the optic chiasma. It is usually white in color. Look for dehiscence.
2. Internal carotid artery (ICA): laterally. It is usually red in color. Look for
3. Possible dehiscence of bony canal of the optic nerve and/or internal carotid artery
4. Recess in between [infraoptic recess]
5. Sphenoid septa which may be attached to the optic nerve and/or the internal carotid artery
6. Maxillary nerve (MN): Laterally and far inferiorly
7. Vidian nerve: inferiorly
8. Sphenoid sinus septum
9. Sphenoid sinus floor
10. Sphenoid sinus roof which is the planum sphenoidal
11. Sella bulge: posterior and superior below optic chiasma [Fig. 42, a-b]

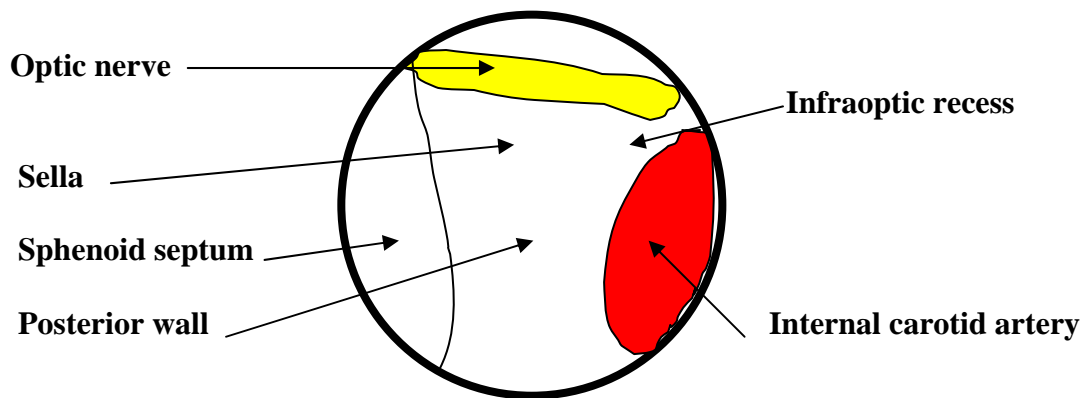


Fig. 42,a- The sphenoid sinus

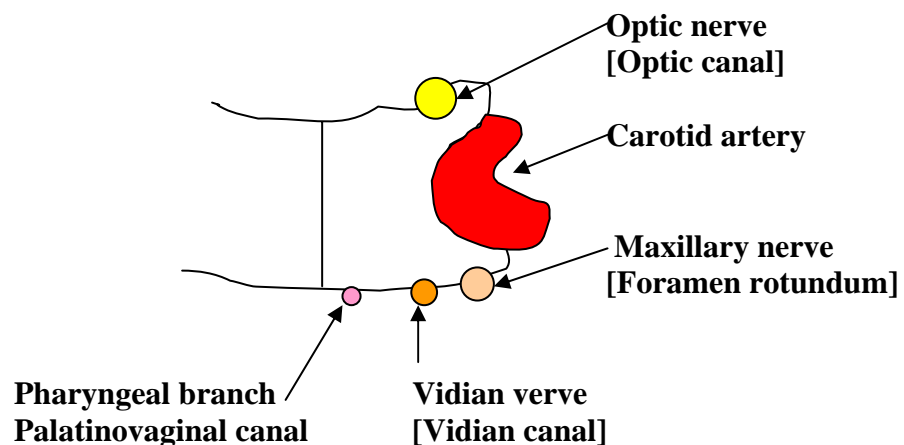


Fig. 42,b- The sphenoid sinus

IV- Do not Do - It is Mentioned to be Condemned [Complications]:

(43) **Bleeding:** define sites of the:

1. Sphenopalatine artery: posterior to the posterior end of the middle turbinate
2. Anterior ethmoid artery: on the ethmoid roof, anterior to the bulla ethmoidalis and posterior to the supraorbital air cell. It may be present in a bony canal or hanging by a mesentery.
3. Posterior ethmoid artery: anterior to the face of the sphenoid on the fovea ethmoidalis i.e. roof of the posterior ethmoids
4. Internal carotid artery: lateral wall of the sphenoid sinus. Try to penetrate it to get blood (blow out).

(44) **Orbital:** define the site of the:

1. Agger cells in relation to the nasolacrimal sac which may lead to **Epiphora**
2. Lamina papyracea in relation to the orbital fat and medial rectus which may lead to **echymosis, emphysema, and/or diplopia.**
3. Optic nerve which may lead to **blindness.**

(45) Identify the agger cell and use the drill it to expose the lacrimal sac.

(46) Identify the lamina papyracea and penetrate it to show the orbital fat (yellow). Then press on the globe from outside to demonstrate bulge of yellowish fat inside the nose. Notice the prolapse of the orbital fat.

(47) Identify the optic nerve and look for any bony dehiscence. Then penetrate it using a dissector if feasible. Then expose it medially to chiasma and laterally to fibrous annulus using the burr.

(48) **CSF leak:-** Identify the:

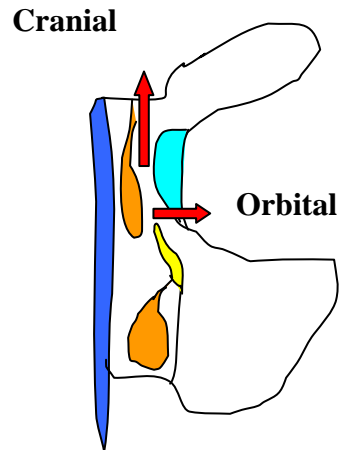
1. Fovea ethmoidalis (FE)
2. Lateral lamella (LL)
3. Cribriform plate (CP)

- Try to determine their:

1. Level
2. Thickness
3. Length

- Then try to penetrate them: fovea ethmoidalis, lamina papyracea and cribriform plate to make a defect in each.

	Thickness	Penetration	Level	Length
Fovea ethmoidalis	Thick	Difficult	High	Long ±
Lateral lamella	Very thin	Very easy	Lower	Short ±
Cribriform plate	Thin	Easy	Lowest	Very short



47,48- Complications

(49) Coronal CT cuts are mandatory to determine the length, thickness, level and directions of the fovea ethmoidalis, lamina papyracea and cribriform plate.

(50) Notice that the lateral lamella is very, very thin especially at the site of passage of the anterior ethmoid artery.

(51) Expose the bone all around the defect you did at the fovea ethmoidalis and or lateral lamella. Take a mucoperichondrial graft from the septum on the other side. Then apply it on the iatrogenic defect with its mucosal surface down. It acts as an excellent seal to the defect.

KNOWLEDGE IS POWER,
BE CAREFUL & TAKE CARE,
Reda Kamel, M.D
Professor of Rhinology
Cairo University – Egypt